

A case of nonconvulsive status epilepticus presenting as dissociative fugue

A Erol,¹ MD; A Yigit,¹ MD; G Dogan,² MD; B Ozer,² MD

¹ Clinic of Psychiatry, Izmir Ataturk Training and Research Hospital, Izmir, Turkey

² Clinic of Neurology, Izmir Ataturk Training and Research Hospital, Izmir, Turkey

Corresponding author: A Erol (aerol@superonline.com)

Nonconvulsive status epilepticus is characterised by changes in behaviour, memory, affect or level of consciousness. We report a case of nonconvulsive status epilepticus precipitated by carbamazepine that presented as dissociative fugue. The patient was a 49-year-old man. He first experienced a tonic-clonic seizure nine years previously and was diagnosed with *grand mal* epilepsy. He had been using carbamazepine 800 mg daily for the last eight years. He had not had any tonic-clonic seizures since carbamazepine was introduced but began to display behavioural disturbances periodically. He also left home many times, and remembered nothing about the period he had been away after he returned. He was hospitalised with a preliminary diagnosis of dissociative fugue. He had recurrent episodes with dissociative symptoms during his stay in the hospital. An electroencephalogram (EEG) and a 24-hour video EEG revealed nothing abnormal. An EEG recording taken during an episode indicated complex partial status epilepticus. Carbamazepine was substituted with valproate, and the patient was discharged in remission.

S Afr J Psych 2013;19(4):226-227. DOI:10.7196/SAJP.458



The relationship between epilepsy and psychiatric disorders has generated interest since ancient times. In recent years, the recognition of psychiatric disorders has gained much importance in patients with epilepsy, and some psychiatric symptoms are found to be an expression of the seizure disorder.^[1]

Traditionally, status epilepticus is defined as continuous or intermittent seizure activity of at least 30 minutes in duration.^[2] Whereas convulsive status epilepticus refers to seizures characterised by motor activity, nonconvulsive status epilepticus may be more difficult to recognise clinically, but should be suspected when there is prolonged alteration in consciousness in the absence of convulsions. The diagnosis requires a high index of suspicion as well as EEG confirmation.^[2]

Mood and anxiety disorders are the most frequent psychiatric comorbidities in patients with epilepsy, followed by psychotic disorders and personality disorders.^[3] Rarely, typical symptoms of dissociative disorders may occur during epileptic attacks, but among epileptic patients with dissociative symptoms, only a minority have concomitant dissociative disorders.^[4]

This paper reports a case of status epilepticus presenting as dissociative fugue.

Case report

The patient was a 49-year-old, male, single, high school graduate. He had first experienced a tonic-clonic seizure nine years before this admission, after he witnessed the murder of a friend. When those seizures began to repeat every 3 or 4 days, he attended a neurology outpatient clinic where he was diagnosed with *grand mal* epilepsy. He was treated with carbamazepine 800 mg/day which stopped the seizures. He used carbamazepine 800 mg/day regularly for eight years and had no further tonic-clonic seizures.

However, eight years ago, a few weeks after the patient was initiated on carbamazepine therapy, he began to display periodic behavioural

disturbances. He exhibited purposeless, agitated, aggressive, and sometimes bizarre behaviours. On occasions, his mother and his sister observed him screaming suddenly, throwing and breaking a cup he was drinking from, or wandering around naked. Sometimes he was looking for something that did not exist. He also left home many times, and after returning, remembered nothing about the period during which he had been away. During one such episode, he was found in an emergency facility 24 hours after he had left home, suffering from multiple stab wounds. However, he could not remember how he came to be there.

When the patient presented at Ataturk Training and Research Hospital's outpatient Clinic of Psychiatry, dissociative fugue was suspected. He was hospitalised for a diagnostic work-up. At the time of his admission, he was on carbamazepine 800 mg/day. His mental state and neurological examination revealed nothing abnormal. A complete blood count, liver and kidney function tests, thyroid profile and urine analysis were within normal limits. A urine drug screen was negative. The serum carbamazepine level was 10.84 µg/ml (within therapeutic levels). Cranial magnetic resonance imaging (MRI) and an electroencephalogram (EEG) did not reveal any abnormalities.

On the 6th day of his hospitalisation, the patient suddenly became agitated. He swept objects off tables and began wandering in the ward. He spilled the contents of garbage bins onto the floor, tried to leave the ward repeatedly, and was confused. His symptoms cleared after a few hours, with complete amnesia of the abnormal behaviour.

A 24-hour video EEG did not reveal any abnormalities. However, similar episodes continued to recur once a week. When it became possible to do an EEG during an episode of abnormal behaviour, it showed continuous generalised polyspike-and-wave discharges. A diagnosis of complex partial status epilepticus was reported according to the EEG recording (Fig. 1). Carbamazepine was substituted with valproate, and the patient was discharged in remission.

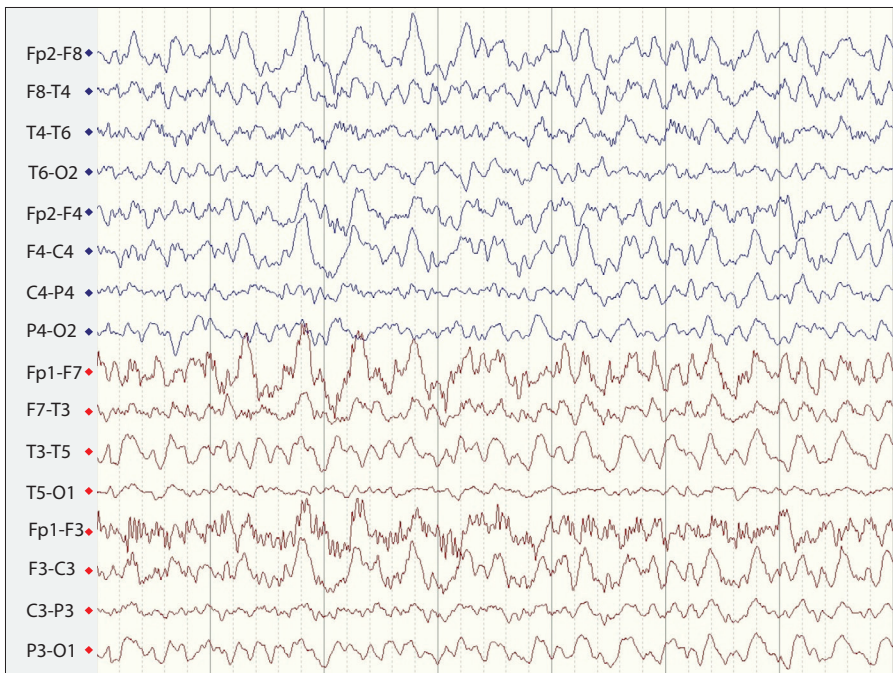


Fig. 1. A diagnosis of complex partial status epilepticus was reported according to the EEG recording.

Discussion

Nonconvulsive status epilepticus is one of the most under-recognised or misdiagnosed epileptic conditions. It is characterised by changes in behaviour, memory, affect, or level of consciousness, often with alteration in muscle tone and fine facial or limb jerks for at least 30 minutes, accompanied by EEG evidence of seizures.^[5] It can be divided into two major forms: generalised with bilateral diffuse synchronous seizures (absence), or partial with lateralised seizures (complex partial).^[6] Absence and complex partial status epilepticus are difficult to distinguish because clinical characteristics may overlap.^[7]

Dissociation has been described as a disruption of the normally integrated functions of consciousness, memory, identity, or perception of the environment and/or the body.^[8] Dissociative disorders and epilepsy share a number of common symptoms that include amnesia, fugue, depersonalisation, derealisation, and identity change.^[4] In addition, some individuals with dissociative disorder also suffer from epilepsy. Moreover, both patients with epilepsy and pseudo-epileptic seizures show high dissociation scores. These overlapping symptoms and concurrent diagnoses can create diagnostic difficulties.^[4]

Our patient had recurrent, episodic dissociative symptoms and fugue episodes over the previous eight years. Traumatic circumstances, leading to an altered state of

consciousness dominated by a wish to flee, are thought to be the underlying cause of most fugue episodes.^[9] Although our patient's episodes started after a traumatic event (he witnessed a murder), his history of *grand mal* epilepsy points to the possibility of nonconvulsive status epilepticus.

The most common clinical features observed during complex partial status epilepticus are confusion, hallucinations, mutism, anxiety, and variable amnesia.^[10] Although some patients may have alterations in muscular tone and fine facial or limb jerks that can help in accurate diagnosis,^[5] our patient never had motor manifestations. Therefore it was not possible to diagnose complex partial status epilepticus until an EEG was performed during an episode of abnormal behaviour.

The EEG revealed characteristic findings, and our patient had all the common clinical features, of complex partial status epilepticus, except mutism. In addition, complex partial status epilepticus has a tendency to recur in a regular pattern, such as every week or every month,^[10] as was the case in our patient.

Nonconvulsive status epilepticus can be precipitated by withdrawal from anti-epileptic drugs, sleep deprivation, excessive alcohol intake, fatigue, psychotropic medications and emotional stress. In recent years, it has come to be understood that anti-epileptic drugs can aggravate pre-existing seizure disorders and trigger new seizure types.^[11] Drugs may

be incorrectly prescribed due to incorrect diagnosis of seizure type, or clinicians may not realise the certain drugs are contraindicated for specific types of seizure.^[11] Two cases have been reported previously in which nonconvulsive status epilepticus, exacerbated by carbamazepine, was misdiagnosed as dissociative and affective disorders.^[12]

Our patient had been on carbamazepine therapy since his behavioural symptoms began, and did not have any other precipitating factors. The substitution of carbamazepine with valproate rapidly ameliorated all symptoms, and tonic-clonic seizures did not reoccur. It is seen that carbamazepine treated his tonic-clonic seizures, but did not prevent episodes of nonconvulsive status epilepticus.

A clinical suspicion of nonconvulsive status epilepticus should be considered in patients with epilepsy with recurrent or episodic behavioural changes, such as bizarre behaviour, fugue, agitation, confusion, and amnesia. In such cases, EEG recording during abnormal behavioural episodes should be performed. Most importantly, it should always be kept in mind that inappropriate anti-epileptic drug treatment can be a precipitating factor for nonconvulsive status epilepticus.

References

- Mirsattari SM, Gofton TE, Chong DJ. Misdiagnosis of epileptic seizures as manifestations of psychiatric illnesses. *Can J Neurol Sci* 2011;38(3):487-493.
- Arman F. Status epilepticus. In: *Epilepsi*. Bora İ, Yeni N, Gürses C, eds. Ankara: Nobel Tıp Kitabevleri, 2008.
- Gaitatzis A, Trimble MR, Sander JW. The psychiatric comorbidity of epilepsy. *Acta Neurol Scand* 2004;110:207-220. [<http://dx.doi.org/10.1111/j.1600-0404.2004.00324.x>]
- Bowman ES, Coons PM. The differential diagnosis of epilepsy, pseudoseizures, dissociative identity disorder, and dissociative disorder not otherwise specified. *Bull Menninger Clin* 2000;64(2):164-180. [<http://dx.doi.org/10.1111/j.1600-0404.2004.00324.x>]
- Kaplan PW. Assessing the outcomes in patients with nonconvulsive status epilepticus: Nonconvulsive status epilepticus is underdiagnosed, potentially overtreated, and confounded by comorbidity. *J Clin Neurophysiol* 1999;16:341-352.
- Engel J Jr, International League Against Epilepsy. A proposed diagnostic scheme for people with epileptic seizures and with epilepsy: Report of the ILAE Task Force on Classification and Terminology. *Epilepsia* 2001;42:796-803.
- Husain AM, Horn GJ, Jacobson MP. Non-convulsive status epilepticus: Usefulness of clinical features in selecting patients for urgent EEG. *J Neurol Neurosurg Psychiatry* 2003;74(2):189-191.
- American Psychiatric Association. *Diagnostic and Statistical Manual of Mental Disorders IV*. Washington, DC: American Psychiatric Press, 1994.
- Simeon D, Loewenstein RJ. Dissociative disorders. In: Kaplan and Sadock's *Comprehensive Textbook of Psychiatry*. Sadock BJ, Sadock VA, Ruiz P, eds. 9th ed. Philadelphia: Lippincott, Williams & Wilkins; 2009.
- Cockrell OC, Walker MC, Sander JWAS, Shorvon SD. Complex partial status epilepticus: A recurrent problem. *J Neurol Neurosurg Psychiatry* 1994;57:835-837.
- Deckers CL, Genton P, Sills GJ, Schmidt D. Current limitations of antiepileptic drug therapy: A conference review. *Epilepsy Res* 2003;53(1-2):1-17.
- Marini C, Parmeggiani L, Masi G, D'Arcangelo G, Guerrini E. Nonconvulsive status epilepticus precipitated by carbamazepine presenting as dissociative and affective disorders in adolescents. *J Child Neurol* 2005;20(8):693-695.